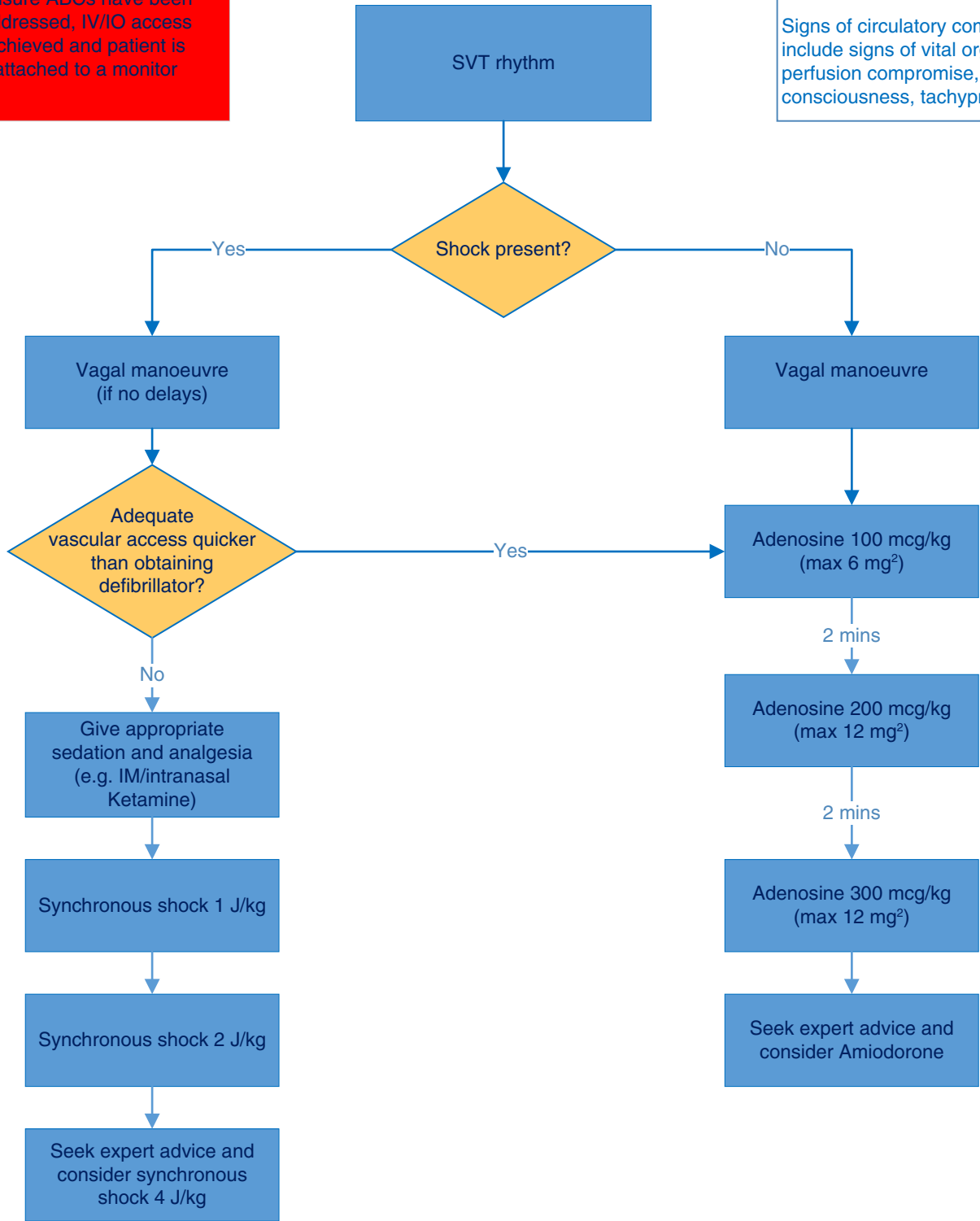


Management of Supraventricular Tachycardia

Ensure ABCs have been addressed, IV/IO access achieved and patient is attached to a monitor

Signs of shock: bradycardia, tachycardia, BP < 5th centile¹, CRT > 2 secs, weak or impalpable peripheral pulses

Signs of circulatory compromise include signs of vital organ perfusion compromise, altered consciousness, tachypnoea



1 See table on inside front cover
2 These are maximum adult doses